

# Doppler-guided hemorrhoidal laser procedure for the treatment of symptomatic hemorrhoids: experimental background and short-term clinical results of a new mini-invasive treatment

Paolo Giamundo · Walter Cecchetti · Luigi Esercizio · Giovanni Fantino ·  
Maria Geraci · Roberto Lombezzi · Michele Pittaluga · Livio Tibaldi ·  
Giovanni Torre · Marco Valente

Received: 16 May 2010 / Accepted: 4 September 2010  
© Springer Science+Business Media, LLC 2010

## Abstract

**Background** According to the “vascular” theory, arterial overflow in the superior hemorrhoidal arteries would lead to dilatation of the hemorrhoidal venous plexus. A 980-nm diode laser-pulsed shot causes shrinkage of tissue. The depth of shrinkage can be regulated by the power and duration of the laser beam. Through a 1000-micron conic fiber, five laser shots generated at a power of 13 W with duration of 1.2 s each and a pause of 0.6 s caused shrinkage of tissues to the depth of approximately 5 mm. Terminal branches of the superior hemorrhoidal artery in the anal canal, if precisely identified through a Doppler signal, can be closed with the use of this laser.

**Methods** A specially designed proctoscope has a small window that allows introducing a Doppler probe whose function is to identify hemorrhoidal arteries. Approximately 3 cm above the dentate line, the terminal branches of the superior hemorrhoidal artery (usually 8–12) are recognized through a clockwise rotation of the proctoscope and progressively fulgurated through a laser optic fiber. The procedure does not require anesthesia and can be performed as an ambulatory treatment.

**Results** Thirty patients (16 men) with second to third grade symptomatic hemorrhoids have been treated with the described technique. The procedure proved to be successful at 3 months’ follow-up in 92% of cases. No major adverse effects or complications were reported. Bleeding was observed in four cases. In two cases surgical hemostasis was necessary. Minor pain that required medication was reported in three cases.

**Conclusions** The hemorrhoidal laser procedure (HeLP) represents a new nonexcisional, mini-invasive treatment for patients suffering from second and third degree hemorrhoids without severe mucosal prolapse. Thermal occlusion of the hemorrhoidal arteries causes a progressive shrinkage of hemorrhoidal cushions. The procedure does not require anesthesia, is technically easy, repeatable, and can be performed as an office treatment.

**Keywords** Hemorrhoids · Dearterialization · Doppler · Laser

Hemorrhoids affect a large percentage of the adult population around the world. In published surveys, actual incidence depends on the enquiry method and varies between 4 and 36% of the population. Its prevalence varies in published papers from 4.4–86% [1, 2].

The search for a painless surgical treatment for hemorrhoids has recently led to the introduction of several mini-invasive procedures based on different rationales. Most of these techniques are nonexcisional and less painful than traditional excisional procedures.

Doppler-guided hemorrhoidal artery ligation (HAL) [3] and transanal hemorrhoidal dearterialization (THD) [4] represent innovative approaches to the cure of hemorrhoids. Both techniques are based on the identification and

---

Presented at the 12th WCES, 14–17 April 2010, National Harbor, MD.

---

P. Giamundo (✉) · L. Esercizio · G. Fantino · M. Geraci ·  
R. Lombezzi · M. Pittaluga · L. Tibaldi · G. Torre · M. Valente  
Department of General Surgery, Hospital S. Spirito, Bra (CN),  
Via Vittorio Emanuele 3, 12042 Bra, CN, Italy  
e-mail: giamundo@hotmail.com

W. Cecchetti  
Department of Chemistry/Physics, University Ca’ Foscari,  
Venice, Italy

ligation of the terminal branches of the superior rectal arteries through a dedicated proctoscope equipped with a Doppler transducer. Dearterialization of terminal branches of the superior hemorrhoidal artery causes progressive reduction in blood flow to the hemorrhoids followed by shrinkage of the hemorrhoidal cushions and a consequent improvement in symptoms. By minimizing anodermal involvement, less postoperative pain and quicker recovery are reported with these techniques.

However, in most cases, locoregional anesthesia, deep sedation, or general anesthesia are necessary to perform these procedures, and in only very few centers patients can be discharged a few hours after surgery.

A new mini-invasive surgical technique—"HeLP"—has recently moved beyond the experimental phase. It follows the same rationale of HAL and THD procedures with the potential advantage of being less invasive and not requiring any anesthesia.

"HeLP" is the acronym for hemorrhoidal laser procedure. In the HeLP procedure, a 980-nm diode laser causes shrinkage of the terminal branches of the superior hemorrhoidal artery without the need of sutures.

As with HAL and THD, the arterial branches are identified through a Doppler in the anal canal and closed with a laser beam approximately 3 cm above the dentate line.

The authors herein report the experimental preliminary data that contributed to establishing the optimal parameters for laser radiant energy delivery. Functional and clinical results in the low and middle term of the first 30 patients treated in a single center with this technique are reported. Symptoms, clinical aspects, and quality of life were prospectively evaluated.

## Patients and methods

From February 2009 to April 2010, 30 consecutive patients underwent the HeLP procedure for symptomatic hemorrhoids. Operative time, morbidity, and functional outcome were prospectively evaluated. The trial was regularly approved by the institutional review committee. All patients participating in the trial signed a specific informed consent.

This procedure was indicated in the case of symptomatic II degree hemorrhoids or in III degree hemorrhoids with moderate mucosal prolapse. Patients with IV degree hemorrhoids and/or those with III degree hemorrhoids and severe prolapse at preoperative proctoscopic evaluation were excluded from the study.

We also excluded patients with thrombosis of hemorrhoidal cushions, anal fissures, anal fistulas, acute IBD, patients treated with other procedures for hemorrhoids during the past year, patients younger than age 18 years or

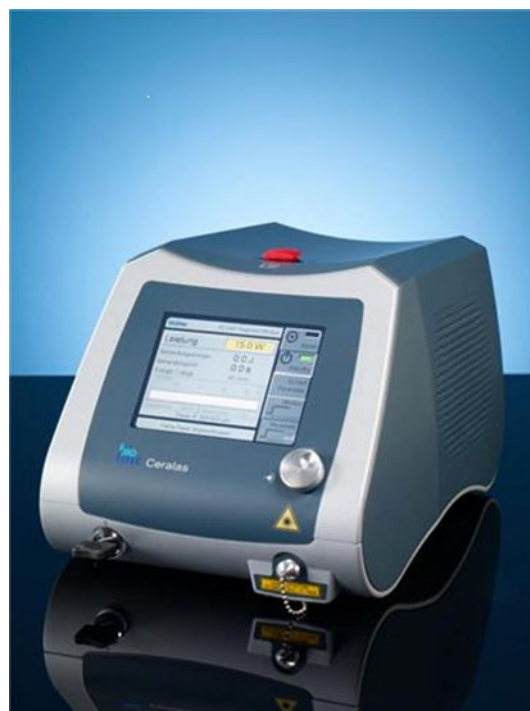older than age 75 years, and patients with obstructed defecation syndrome or significant fecal incontinence (Wexner's fecal incontinence score > 7).

Before the operation all patients underwent a colonoscopy or proctosigmoidoscopy to exclude other causes of bleeding not associated with hemorrhoids. Preoperative symptoms, including type of medical treatments, were registered in a database. All patients at the time of the first outpatient visit underwent an accurate proctoscopy. Goligher and PATE classifications [5] for hemorrhoids were used for preoperative and postoperative staging purposes.

Before the operation, a specific informed consent was signed by all patients. All patients agreed to participate in the follow-up. The patients' follow-up was scheduled at 1, 2, and 4 weeks, and 3, 6, and 12 months postoperatively. Postoperative evaluation of the degree of hemorrhoidal enlargement was conducted by a surgeon who was blinded at preoperative evaluation. VAS assessment of quality of life and pain was administered and supervised by a blinded and independent observer (surgical resident) at follow-up.

## Experimental studies

A 980-nm diode laser (Fig. 1) has several applications in different surgical fields (urology, vascular surgery, plastic surgery, vertebral canal surgery). Compared with other



**Fig. 1** 980-nm diode laser

types of lasers, it has the advantage of being very accurate, effective, safe, manageable, and of small dimensions.

The choice for the optimal wavelength, timing, and mode of laser radiant energy delivery has to take into account the type of tissues encountered by the laser beam. In particular the laser energy has to cross the rectal mucosa without causing undesired damage or bleeding and must be absorbed by the arterial vessel to trigger the thermal occluding effect.

With this regard, before clinical laser application, experimental “in vitro” studies on pig tissues have been conducted. The goal to be accomplished was to find the optimal parameters for obtaining a high absorption of energy by the arterial blood and minimal damage to the mucosa crossed by the laser beam.

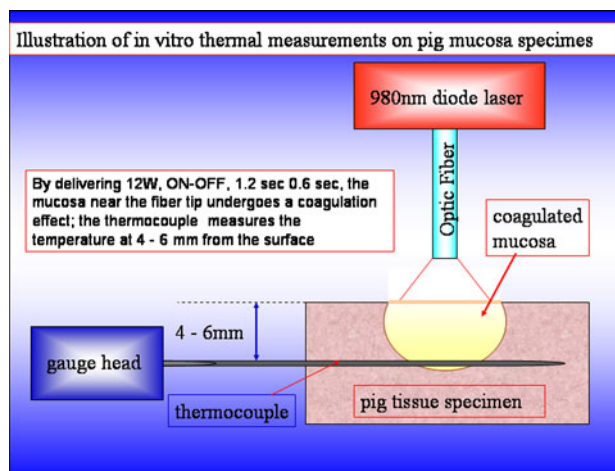
The study of water and blood spectra of absorption between 800 and 1500 nm gave us the necessary information for the selection of the optimal laser wavelength necessary for the HeLP technique (Fig. 2). The wavelength of 960–980 nm seemed to provide the most adequate conditions for our purpose.

Ten pig tissue specimens of rectal wall were treated with 980-nm diode laser beam delivered through a 600-micron flat tip optic fiber at increasing energy (from 10–15 W) in a pulsed mode.

Thermal effects on tissue were measured through thermocouple gauges implanted in the rectal wall at different depths (Fig. 3). Slices of 1-mm thickness were then obtained from treated tissues to measure the effect of laser radiant energy at different depths.

The space-time photoselectivity of lasers is determined by the laser power and erogation time. The actual depth of coagulating/burning effect of the laser on tissues depends on the power density and the erogation time.

The results of the experimental trial showed that five laser shots delivered at the energy of 13 W in a pulsed



**Fig. 3** Experimental thermal measurements after laser shots on pig tissues

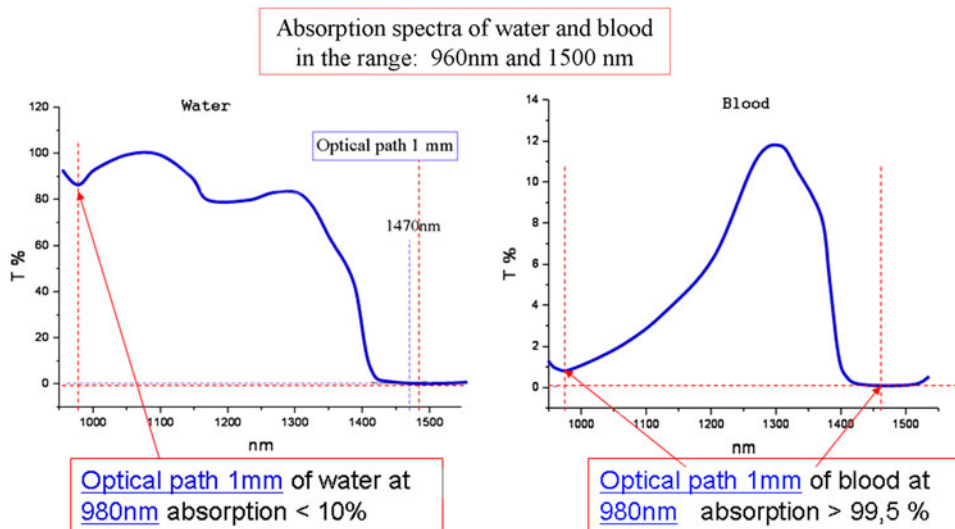
mode (1.2 s ON, 0.6 s OFF) caused a shrinkage of tissue to an average depth of 5 mm (range 4–6 m). Delivery of laser radiant energy through a pulsed mode caused effective shrinkage of underlying tissue, whereas a continuous mode enhanced the burning and vaporization effect (Fig. 4).

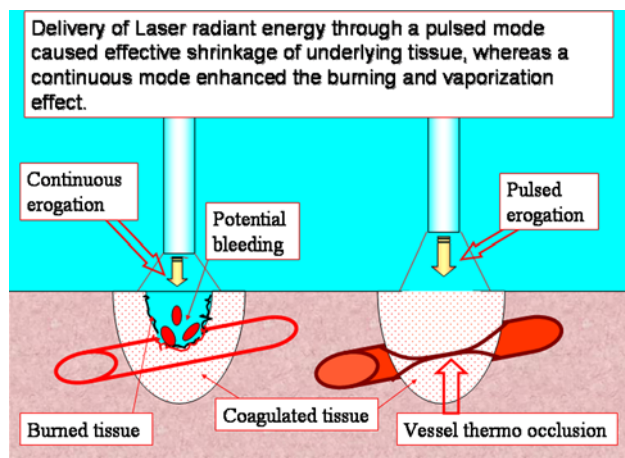
**Technique**

No anesthesia is required for the HeLP procedure. Analgesic drugs can be administered intraoperatively if requested by the patient. No antibiotic prophylaxis is required.

A specially designed disposable proctoscope is inserted into the rectum with the patient in the lithotomy position (kit for “HeLP”; Biolitec AG, Bonn, Germany). At the distal end of the proctoscope, there is a small window that holds a Doppler transducer. The Doppler probe (20 MHz

**Fig. 2** Pattern of laser radiant energy absorption

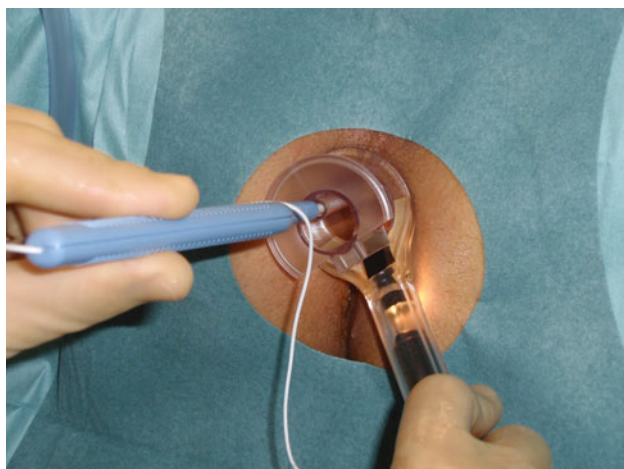




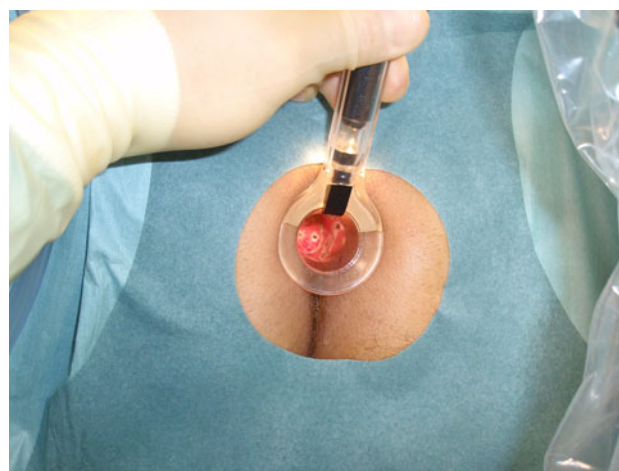
**Fig. 4** Thermal occlusive effects of laser on tissues

probe of 3 mm diameter) allows identification of the terminal branches of the superior hemorrhoidal arteries approximately 3 cm proximal to the dentate line (Fig. 5). Once the arterial flow is located, the Doppler probe is removed and replaced with a 1,000-micron laser optic fiber. Closure of the artery is performed through a laser beam (13 W: 5 pulsed shots of 1.2 s each with 0.6 s pause). Actual closure of the artery is checked by reintroducing the Doppler probe, because it should be associated with disappearance of the Doppler sound. In case of persisting flow, another sequence of two laser shots is delivered in the same point.

A clockwise rotation of the proctoscope allows the accurate localization of all the terminal branches of the hemorrhoidal artery, which are then sequentially treated with the laser beam. A maximum of 12 arterial branches are treated—one at each o'clock hour (Fig. 6).



**Fig. 5** HeLP technique: intraoperative identification of the artery with Doppler probe



**Fig. 6** HeLP technique: effect of laser shots on rectal mucosa

## Results

The HeLP procedure was performed on 30 consecutive patients of mean age  $47 \pm 12.6$  (median, 46 (range, 24–70)) years. There were 16 men and 14 women. Fourteen patients had grade II hemorrhoids and 16 had grade III hemorrhoids with moderate mucosal prolapse at proctoscopy and a medical history of rare episodes of prolapse manual reduction.

Symptoms reported by the patients were: bleeding in 21 cases, pain in 18 cases, and recurrent hemorrhoidal acute syndrome (pain, bleeding, mucous discharge) lasting for a mean of 6 consecutive days at least twice per year during the past 5 years in 23 cases.

Eight patients had skin tags that never were the main complaint. All patients had tried a standardized preoperative therapeutic regimen consisting of high-fiber diet, diosmin, suppositories, and sitz baths.

Four patients had been treated previously for the disease in the past (2 stapled mucopexy, 1 THD, 1 THD + rubber band ligation), but none of them during the past year. The procedure was conducted without any kind of anesthesia.

In three patients, a minor analgesic drug (ketorolac 40 mg and/or paracetamol 500 mg) was administered during the operation at the patient's request. The mean operative time was  $9.5 \pm 2.3$  (median, 10 (range, 6–18)) minutes. On average,  $10.8 \pm 1.2$  arteries (median, 11 (range, 8–12)) were localized and treated with the laser beam.

No associated procedures were performed. Bleeding was observed intraoperatively in four cases (13.4%). No blood transfusion was necessary in all cases. Two cases of intraoperative bleeding were successfully treated with laser. In two other patients, one hemostatic suture was necessary to close the bleeding artery.

In our series, all patients but one were discharged approximately 2 h after the operation and were allowed to resume normal activities with no restrictions. The remaining patient was discharged the day after; this was one of the patients who had intraoperative bleeding requiring hemostatic suture.

Three patients (10%) developed moderate postoperative pain within the first 24 h and were treated with minor analgesic drugs. Mean postoperative pain score (VAS 0–10) during the first 72 h was  $1.4 \pm 1.71$ .

Three patients complained of mild dyschezia that lasted approximately 5 days and required no particular treatment. Two of these three patients had been treated 2 years earlier with a stapled mucopexy ( $n = 1$ ) and THD ( $n = 1$ ). At follow-up no thrombosis, edema, or acute inflammatory episodes were reported.

At 1 week follow-up, mucosal scars covered with some fibrin deposits were found in the vast majority of patients at proctoscopy in the sites of laser shots.

At 2 weeks follow-up, most of the rectal scars were no longer recognizable in most patients.

At 1 month follow-up, no major complications were reported. Twenty-three patients (of 30; 77%) showed a downgrading of the hemorrhoids: 14 patients who had preoperatively grade III showed only grade II or grade I haemorrhoids, and 9 patients changed from grade II to grade I. Improvement of symptoms (bleeding, pain) was reported in 26 of 30 patients (86%).

At 3 months follow-up (24 patients), improvement of symptoms was reported in 22 patients (91.7%; Table 1). The longest follow-up was at 12 months for three patients and 10 months for other nine patients. Of these 12 patients, improvement of symptoms reported at 3-month follow-up remained unchanged in 11 cases. In one of these patients,

two episodes of light bleeding were reported, which required medical treatment (bioflavonoids, sitz baths).

Self-assessed quality of life score (VAS 0–10) improved in all patients but two (93%): at 3 months follow-up it was 8.8 (range 7–10). Improvement of quality of life did not change at longer follow-ups.

At a mean follow-up of 5.8 months (range 1–12), the overall success rate was 93% (28 patients) with 7% of residual unchanged hemorrhoids and persisting symptoms. No correlation was found between clinical outcome and number of arteries found at operation and closed through laser shots.

## Discussion

Although the real pathophysiology of hemorrhoidal disease remains controversial, the “vascular” theory has recently been considered a very likely potential cause of hemorrhoids. According to this theory, arterial overflow in the superior hemorrhoidal arteries would lead to dilatation of the hemorrhoidal venous plexus based on the anatomical findings of arteriovenous hemorrhoidal shunting system without capillary interposition.

This theory does not exclude the “mechanical” explanation according to which the muscular fibroplastic supportive tissue of the hemorrhoidal plexus would degenerate in patients suffering from hemorrhoidal disease. Based on the “vascular” theory, the reduction in blood flow to the hemorrhoids should lead to shrinkage of the hemorrhoidal piles and consequent symptomatic improvement.

Recent anatomic studies demonstrated that the terminal branches of the superior rectal artery exclusively contribute to the arterial blood supply of the hemorrhoidal plexus. In addition, in patients with hemorrhoidal disease, these branches are dilated with an associated increase in blood flow [6, 7].

Furthermore, the arteries supplying the corpus cavernosum recti are not found in the locations stated in the literature [8].

With regard to the above-mentioned pathophysiology theories and these anatomic findings, the relatively new, nonexcisional, surgical techniques for hemorrhoids—HAL Doppler and THD—appear to be good treatment options for symptomatic hemorrhoids. Both techniques are based on the reduction of the hemorrhoidal arterial flow that feeds the hemorrhoidal plexus through a Doppler-guided identification and ligation of the terminal branches of the superior rectal artery.

Giordano et al. [9] recently published a systematic review of transanal hemorrhoidal dearterialization, which reported the analysis of 17 articles with a total of 1,996 patients. Good functional results have been reported in the

**Table 1** Overall clinical results

Symptom	No. of patients ( $N = 30$ ) <sup>a</sup>	%
I.O. bleeding	4 (2 laser, 2 sutures)	13.3
Dyschezia	3	10
Itching	0	0
Pain <sup>b</sup>	2	6.6
Pain at evacuation	2	6.6
Use of minor analgesic drugs	3	10
Satisfaction	28/30	93
Downgrading of hemorrhoids	23/30 (1 month)	77

Mean operative time:  $9.5 \pm 2.3$  min

Mean arteries closed:  $10.8 \pm 1.2$

Mean follow-up: 5.8 (range, 1–12) months

<sup>a</sup> 16 men; 14 women: mean age,  $47 \pm 12.6$  (range, 25–70) years

<sup>b</sup> Mean p.o. (first 72 h) pain score (VAS 0–10):  $1.4 \pm 1.71$

vast majority of patients, even at long-term follow-up, especially in patients suffering from second- and third-degree hemorrhoids. Different results were obtained on fourth-degree hemorrhoids. In these cases, recurrence or persistence of prolapse reached rates of up to 50–60% with some better outcome when an additional mucosopexy was performed.

The “HeLP” technique is a new surgical procedure that follows the same rationale of HAL and THD techniques with regard to hemorrhoidal dearterialization. However, with this procedure, the closure of terminal branches of the superior rectal artery is achieved by means of a laser beam. The technique has recently surpassed the experimental phase and is gaining interest among the scientific community.

As in the other nonexcisional techniques mentioned above, the sensitive anoderm below the dentate line is avoided, minimizing postoperative pain and promoting quicker recovery times. “HeLP”—different from the other procedures—does not require any kind of anesthesia. This explains the exceptionally quick recovery and the early discharge of patients from the hospital after the procedure. Laser radiant energy is delivered approximately 3–4 cm above the dentate line where arterial branches have a maximum diameter of 2 mm and tend to emerge toward the mucosal surface [8].

Due to preferential thermal coagulating effect on blood, the shrinkage effect of the laser on submucosal arteries is more selective and periarterial damage of the mucosa is extremely reduced. This also explains a less curative effect on mucosal prolapse after this procedure compared with HAL or THD, where scarring and retraction of the rectal mucosa are more commonly reported.

Consequently the indications for the HeLP procedure should be restricted only to second-degree or third-degree hemorrhoids with minimal mucosal prolapse. Nevertheless, very often there is a poor correlation between the presence of debilitating symptoms and the appearance of the hemorrhoids. In fact, the grading of hemorrhoids, according to common classifications, does not always correlate with severity of symptoms. Sometimes severe-looking hemorrhoids with third- or fourth-degree prolapse may cause relatively few symptoms, whereas pruritus ani, debilitating bleeding, and recurrent acute pain can be associated with second-degree or third-degree hemorrhoids with initial prolapse. In these cases, radical excisional techniques, such as Milligan and Morgan hemorrhoidectomy or stapled hemorrhoidopexy, could be considered “overtreatment”—not to mention the high morbidity rate and the frequent incidence of severe complications reported with these techniques. The HeLP procedure can be considered a more viable option in these selected cases.

In our series, at 1-month follow-up, 77% of patients showed a downgrading of hemorrhoidal appearance. At

3 months, improvement of symptoms was reported in 91.7% of patients. Overall success rate at a mean follow-up of 5.8 months was 93%.

In most cases, the clinical outcome reported at 3 months’ follow-up did not change at longer follow-ups, meaning that improvement of symptoms or failure of the technique are usually evident 3 months after the operation and does not change in the following months.

Postoperative morbidity rate was very low. In particular, pain was almost absent in the vast majority of cases with use of minor analgesic drugs in only 10% of patients postoperatively. Intraoperative bleeding was an unexpected complication in four cases of our series, but a surgical hemostasis was necessary only in two cases (6.6%).

Previous applications of diode laser for the treatment of hemorrhoids included intrahemorrhoidal (endoluminal) laser radiant delivery [10] or submucosal arterial closure without Doppler assistance [11]. In the first technique, intraoperative pain and bleeding cannot be avoided. In the second procedure, the absence of Doppler guidance for arterial localization is a potential cause of clinical failure. In fact, accurate Doppler-guided localization of terminal branches of superior rectal artery is crucial due to a great variation in the number and position of the arteries, as clearly reported in published studies [7, 8].

The first published paper on a similar laser procedure [12] reported the results of 200 patients treated with different laser fibers (from 600 nm to 1,000 nm optic fibers) and with a laser radiant energy delivered at a power varying from 10 to 25 W. A somewhat successful clinical outcome was reported in the majority of patients. However, in that study, patients were retrospectively evaluated and overall technical and clinical data were not homogeneous.

No studies with long-term follow-up have been published yet on this procedure.

Should good clinical results after the HeLP technique be confirmed after longer follow-ups, it would be interesting to compare this treatment to simple medical conservative treatment (tablets, ointments) and to determine whether the laser procedure could stop the natural progression of hemorrhoidal disease toward prolapsing—higher degree hemorrhoids that would require more radical surgery. Although this was not the case in this series, the procedure can be potentially repeated on the same patient in case of partial or complete failure of the first treatment.

The HeLP technique can be compared to a well established mini-invasive treatment for hemorrhoids: the rubber band ligation. Both techniques do not require anesthesia and can be performed as office procedures. Potential advantages of rubber band ligation could be a better performance on mucosal prolapse whereas the laser procedure should give better results in case of persistent bleeding without the need of multiple operative sessions. A

prospective, randomized, clinical trial is currently being conducted at our institution to compare these two techniques (unpublished data, Giamundo et al. 2010).

Finally, in times of scarce financial resources, an analysis of cost of the various surgical procedures to treat hemorrhoids is increasingly important. In our institution, the HeLP procedure has a total cost of approximately 700 euros per patient (approximately US\$900). These figures include the cost of the disposable instruments, the surgeon/nurses fees, and the office occupancy. The laser and the Doppler devices are given to our institution as “free of charge lease” (“comodato uso”). The cost of rubber band ligation is approximately 230 euros per patient (approximately US\$300). This does not take into account the potential need for multiple sessions in the same patient. The cost of other surgical procedures for haemorrhoids, such as THD or PPH, are considerably higher because the cost of 1-day hospital admission, anesthesia, and operating room occupancy need to be added to the costs of the disposable equipment (approximate total cost of both THD and PPH: 1900 euros = approximately US\$2,400). However, PPH and THD procedures are indicated in more advanced cases of hemorrhoidal disease.

## Conclusions

On the basis of the available evidence, the hemorrhoidal laser procedure (HeLP) is safe, repeatable, easy to perform, and can be considered as an effective alternative for the treatment of symptomatic hemorrhoids in the absence of severe mucosal prolapse. Longer follow-ups and randomized trials are needed to establish the exact role of this procedure in the algorithm of treatments for hemorrhoids. In fact no one treatment fits all patients. The HeLP technique can be considered as part of the armamentarium of colorectal surgeons to cure hemorrhoids.

**Disclosures** Dr. Paolo Giamundo, Prof. Walter Cecchetti, Dr. Luigi Esercizio, Dr. Giovanni Fantino, Dr. Maria Geraci, Dr. Roberto

Lombezi, Dr. Michele Pittaluga, Dr. Livio Tibaldi, Dr. Giovanni Torre, and Dr. Marco Valente have no conflicts of interest or financial ties to disclose.

## References

- Loder PB, Kamm MA, Nicholls RJ, Phillips RKS (1994) Haemorrhoids: pathology, pathophysiology and aetiology. *Br J Surg* 81:946–954
- Bleday R, Pena JP, Rothenberg DA, Goldberg SM, Buls JG (1992) Symptomatic hemorrhoids: current incidence and complications of operative therapy. *Dis Colon Rectum* 35:477–481
- Morinaga K, Hasuda K, Ikeda T (1995) A novel therapy for internal hemorrhoids: ligation of the hemorrhoidal artery with a newly devised instrument (Moricorn) in conjunction with a Doppler flowmeter. *Am J Gastroenterol* 90:610–613
- Dal Monte PP, Tagariello C, Sarago M, Giordano P, Shafi A, Cudazzo E, Franzini M (2007) Transanal haemorrhoidal dearterialisation: nonexcisional surgery for the treatment of haemorrhoidal disease. *Tech Coloproctol* 11:333–338
- Gaj F, Trecca A (2004) PATE 2000 Sorrento: a modern, effective instrument for defining haemorrhoids. A multicentre observational study conducted in 930 symptomatic patients. *Chir Ital* 56:509–515
- Aigner F, Bodner G, Conrad F, Mbaka G, Kreczy A, Fritsch H (2004) The superior rectal artery and its branching pattern with regard to its clinical influence on ligation techniques for internal hemorrhoids. *Am J Surg* 187:102–108
- Aigner F, Bodner G, Gruber H, Conrad F, Fritsch H, Margreiter R, Bonatti H (2006) The vascular nature of hemorrhoids. *J Gastrointest Surg* 10:1044–1050
- Schuurman JP, Go PMNYH, Bleys RLAW (2009) Anatomical branches of the superior rectal artery in the distal rectum. *Colorectal Dis* 11:967–971
- Giordano P, Overton J, Madeddu F, Zaman S, Gravante G (2009) Transanal hemorrhoidal dearterialization: a systematic review. *Dis Colon Rectum* 52:1665–1671
- Plaper H, Hage R, Duarte J, Lopes N, Masson I, Cazarini C, Fukuda T (2009) A new method for hemorrhoid surgery: intra-hemorrhoidal diode laser, does it work? *Photomed Laser Surg* 25:819
- Karahaliloglu AF (2007) First results after laser obliteration of first and second degree hemorrhoids. *Coloproctology* 29:329–336
- Salfi R (2009) A new technique for ambulatory hemorrhoidal treatment. *Coloproctology* 31:1–7